

The ugly face of doping

Peter A Gerber, Gabriela Kukova, Stephan Meller, Norbert J Neumann, Bernhard Homey

Lancet 2008; 372:

Department of Dermatology,
Heinrich-Heine-University,
Duesseldorf, Germany
(PA Gerber MD, G Kukova MD,
S Meller MD, NJ Neumann MD,
B Homey MD)

Correspondence to:

Dr Peter Arne Gerber,
Department of Dermatology,
Heinrich-Heine-University,
Moorenstraße 5,
40225 Düsseldorf, Germany
peterarne.gerber@uni-
duesseldorf.de

Various cases in professional sports have brought the matter of doping—the use of performance-enhancing drugs—to the attention of the broad public. Here, we present a case of doping in a 21-year-old amateur bodybuilder. The man presented to our clinic feeling generally unwell. He was subfebrile and had massive, deep ulcerations, abscesses, and pustules located on his chest and upper back (figure). Persistent questioning revealed a history of continuous abuse of anabolic-androgenic steroids (testosterone enantate 250 mg plus metandienona 30 mg twice weekly), which was consistent with the diagnosis of a severe acne conglobata that was anabolic-androgenic steroid induced. Additional investigations showed a substantial impairment in sperm concentration and reduced testicular volume. Skin lesions showed rapid improvement after discontinuation of anabolic-androgenic steroid abuse and with antiseptic and antibiotic therapy. However, the extensive scarring is likely to remain with the young man for the rest of his life.

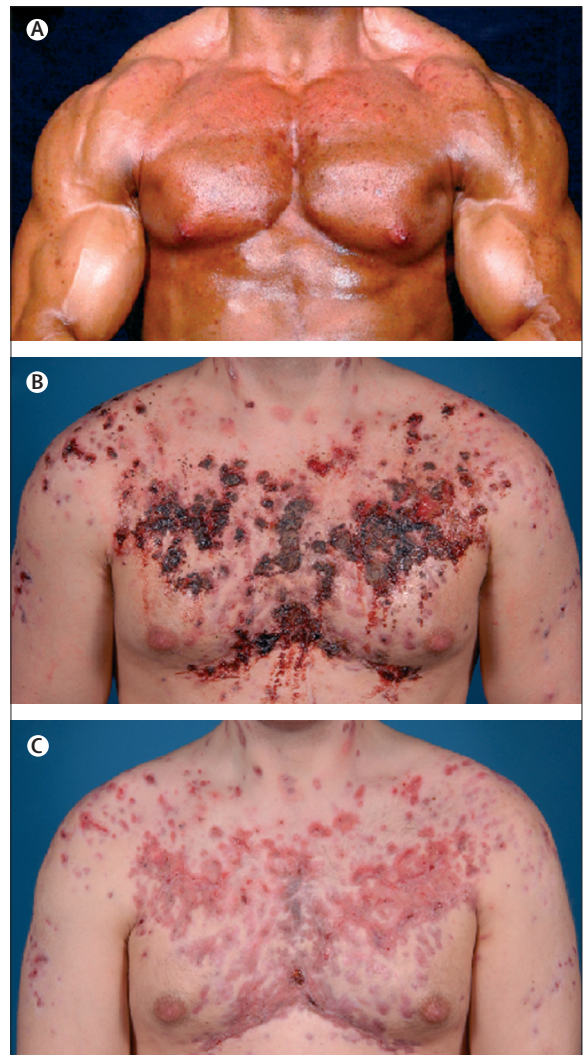


Figure: Severe acne conglobata induced by anabolic-androgenic steroids
The patient at the time of his ideal body image; the 21-year-old bodybuilder had a history of anabolic-androgenic steroid abuse (A). Severe acne conglobata (B); lesions include papules, pustules, abscesses, and deep ulcerations. Patient after 6 weeks of antiseptic-antibiotic therapy (C).